

## Quinacrine hydrochloride drug eruption (tropical lichenoid dermatitis)

*Its early and late sequelae and its malignant potential: A review*

Franz Bauer, M.D.

Melbourne, Victoria, Australia

The totality of effects of a particular drug on patients cannot be truly assessed until many patients have taken it. In order to assess the side effects of any drug, many thousands of patients may have to be observed, and the observation may have to extend over decades.

Quinacrine hydrochloride (quinacrine) was used as a malarial-suppressive drug by allied soldiers during World War II. The most commonly occurring side effect was a drug eruption. This at times led to permanent sequelae at an early stage. Further observation revealed late sequelae occurring 7 to 17 years after the war. Two of these late sequelae were observed to become malignant, and in most cases the palmar aspect was involved. This is an area which rarely shows malignant change. It has been observed that quinacrine can be instrumental in inducing skin cancers as late as 34 years after its ingestion. (*J AM ACAD DERMATOL* 4:239-248, 1981.)

After the Japanese Army entered World War II and invaded Southeast Asia, the supply of quinine, which was then the main antimalarial drug, was lost to the allied forces. Quinacrine,\* a yellow dye which had been used as an antimalarial for a relatively short time, was chosen as a substitute. It was manufactured mainly in the United States of America and, to a lesser extent, in Great Britain. The drug was tested on many hundreds of Australian soldier volunteers at the Medical Research Unit which was attached to the 116th Australian General Hospital near Cairns. As I was at that time in charge of the dermatologic patients of this Australian General Hospital, my association with quinacrine medication goes back many years. The official verdict was that this drug was a highly effective antimalarial drug and was free from seri-

ous side effects. However, this prediction was found to be overly optimistic, because no drug can be fully evaluated until many thousands have taken it, and these same patients have to be under observation for many years (in this instance up to 35 years).

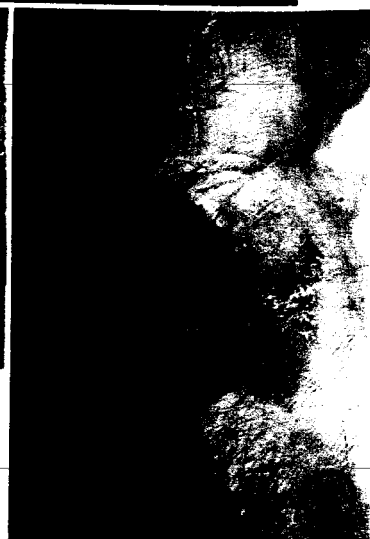
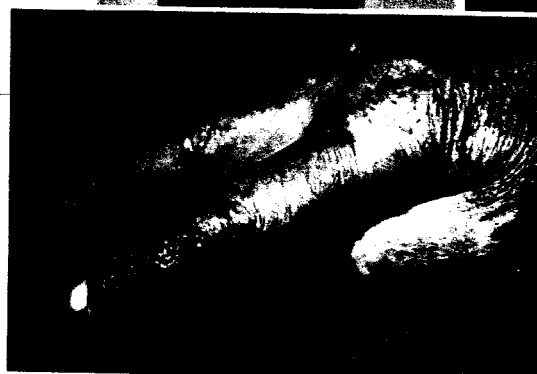
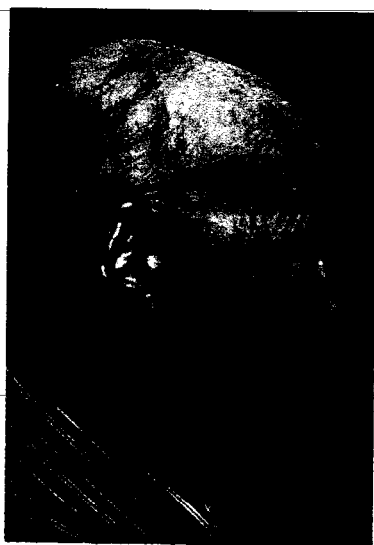Quinacrine is absorbed in all the tissues of the body. Besides mild disturbances such as nausea, headaches, eosinophilia, and anemias, serious side effects were observed,<sup>1-4</sup> some even leading to death. Most organs were involved at times, and fatal cases of acute yellow atrophy of the liver and aplastic anemia were observed. Other organ involvements were associated with nephritis, polyneuritis, pneumonia, and psychosis, but these associations were not proved beyond doubt.

The skin, however, was the most frequently affected organ and was involved once in every two thousand servicemen who were on suppressive quinacrine therapy in a dosage of 100 mg daily.<sup>5</sup> In hyperendemic areas of the Southwest Pacific,

From the Department of Veterans' Affairs, Melbourne.

Reprint requests to: Dr. F. Bauer, 100 Collins St., Melbourne 3000, Australia.

\*Atebrin; Atabrine; mepacrine.



Figs. 1-6. For legends, see opposite page.

where a daily dosage of 200 mg of quinacrine was taken, this drug eruption occurred as frequently as in five hundred American servicemen."

The dermatologic profession was soon aware of ocular skin eruption being caused by quinacrine ingestion. Because of security reasons, this knowledge was not permitted to be passed on beyond some of the medical personnel involved in the care of these soldiers, and it was strictly kept from the troops. This policy was carried out to such a degree that servicemen with a diagnosed quinacrine eruption were not taken off the offending drug until 6 weeks after they had been evacuated to the mainland of Australia, the same routine as applied to all other sick or wounded soldiers. This meant that the causative drug was administered to our patients, on an average, for over 4 months after the onset of their drug eruption (Table 1).

The first official reports were published at the end of the war. Sulzberger and Baer, in their comment in the 1946 *Year Book of Dermatology and Syphilology*, described quinacrine dermatitis as a polymorphous type of eruption consisting of eczematous, eczematoid, lichenoid, lichen planus-like lesions, erythematous and atrophic-like changes, and pigmentary changes. These types of changes can be observed consecutively or can occur simultaneously, or one type of lesion may predominate.

Nisbet<sup>8</sup> reported lichenoid lesions in 12% of patients with quinacrine dermatitis. The eczematoid group comprised 80% of the patients, and 8% suffered from exfoliative dermatitis. Patients with the lichenoid eruption presented a bizarre picture of peculiarly pigmented, slate-blue to purple, hy-

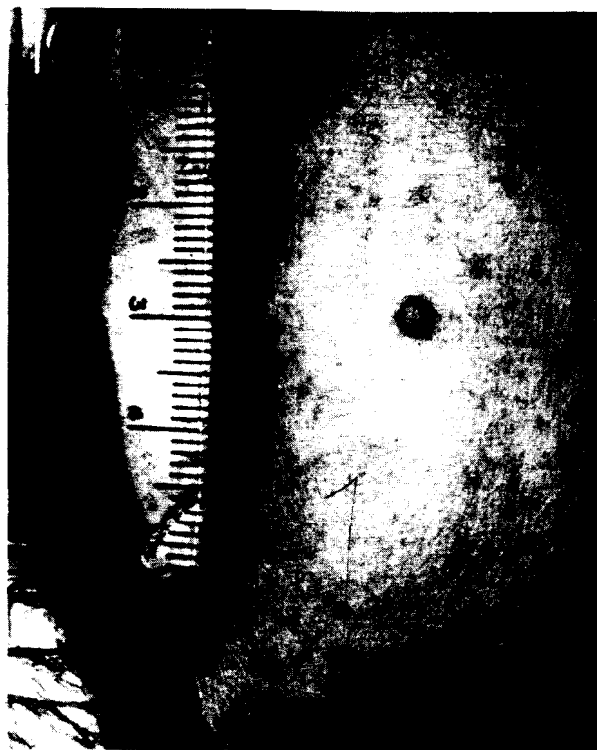

Fig. 7. Lichen planus nodule on depigmented skin. Atrophic changes of fingers.

perrophic lichenoid lesions. Mucous membrane lesions resembled leukoplakia or lichen planus. The eczematoid group presented with chronic dry or exudative eruptions.

Servicemen taking 100 mg of quinacrine daily developed the first changes of a drug eruption after a minimum of 6 weeks," even though I saw three patients from one battalion, two of them with a severe lichenoid eruption, who had taken quinacrine, 100 mg daily, for only 4 weeks.

Fig. 1. Partial alopecia of scalp, eyebrows, and beard area. Pigmentation and marked atrophy of cheek. Hypopigmented scalp scar of mid ear caused by treatment of squamous cell carcinoma. Early peculiar red plaque posterior to and below ear.

Fig. 2. Atrophic changes of hands mimicking disseminated lupus erythematosus.

Fig. 3. Peculiar red plaque sequela of index finger and keratodermatous palm. (From Bauer F: *Australas J Dermatol* 6:311-319, 1962.)

Fig. 4. Silvery, scaly, purplish atrophic sequelae.

Fig. 5. Malignant change in peculiar red plaque. Multifocal malignancy with two separate squamous cell carcinomas. (From Bauer F: *Australas J Dermatol* 19:9-12, 1978.)

Fig. 6. Peculiar red scaly plaque surrounding the larger part of the graft.



**Fig. 8.** Histopathology of lichen planus nodule. Lichen planus-like reaction. (Hematoxylin-eosin stain; x 100.) (From Bauer F: *Australas J Dermatol* 6:311-319, 1962.)

Patch tests to quinacrine were unreliable and frequently negative in patients with quinacrine eruptions.<sup>9</sup>

The damaging effect of quinacrine did involve various structures of the skin, possibly due to a particular sensitivity of this structure to the toxic effects of the drug, its excretion through the sweat apparatus, and the high concentration of the drug in keratin. If the pigment-producing apparatus of the skin was damaged, then this could lead to permanent depigmentation, at times associated with spotty hyperpigmentation. Damage to the hair follicles led to alopecia, sometimes very widespread (Fig. 1). Sweat glands and sweat duct damage caused anhidrosis, usually from the nipples downward, and, if widespread, the anhidrosis was associated with tropical asthenia. Damage to nails led to deformed type of nails and even to their shedding. If the skin, in its totality, was damaged, then this led to gross atrophy. The most severe degree of atrophy was not unlike that seen in widespread lupus erythematosus (Fig. 2).

The mucous membranes of the mouth, when damaged, showed ulcerative and leukoplakic changes.

However, in a small number of patients, the damage led to hypertrophy and abnormality of keratinization, causing keratoderma and warty keratotic outgrowths on the palms.

Schmitt et al, in 1945,<sup>10</sup> reported that patients with quinacrine drug eruptions developed severe sequelae which usually were of a temporary nature. However, in a small number of servicemen, these sequelae became permanent, and some even progressed for years.<sup>11-13</sup>

In most patients a combination of any of these sequelae occurred, the most predominant sequela being that of atrophy of varying degrees.

Schmitt<sup>11</sup> reported recurrent eczematoid dermatitis occurring several years after the war in a small number of patients who had suffered from the eczematoid variety of quinacrine drug eruption. His interpretation of this recurrent dermatitis<sup>12</sup> was that "specific eczema triggered off by quinacrine, became a non-specific type."

Schamberg<sup>13</sup> wrote a review in 1953 reporting a chronic or remittent eczematous, lichenoid, or weeping pruritic eruption, which he named "post-Atabrine dermatitis." This type of involvement occurred in patients with permanent sequelae, but it represented only a small number of patients who had suffered from quinacrine dermatitis.

Seventeen years after the war, Bauer<sup>14</sup> described a new group of sequelae in a series of eleven ex-servicemen with quinacrine eruptions which he named active sequelae. He named the previously occurring sequelae inactive sequelae, as they had stopped progressing many years previ-

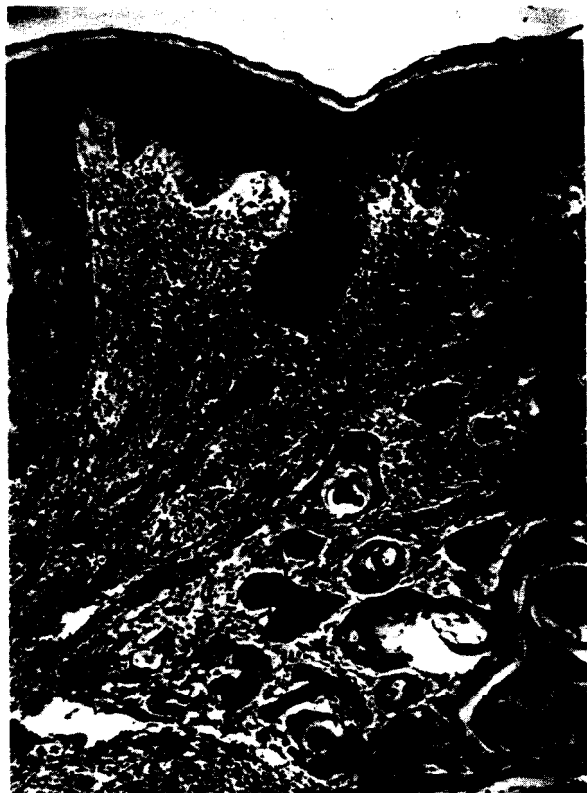
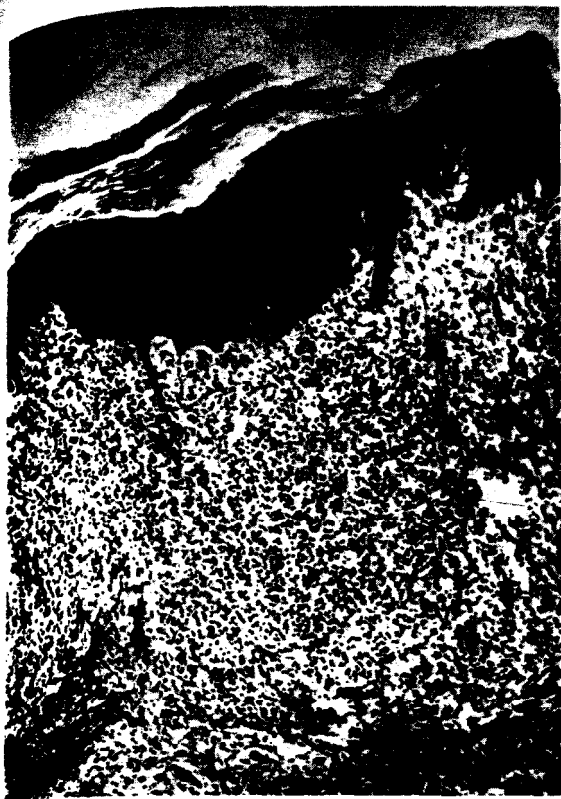
Fig. 9. Histopathology of peculiar red plaque. Lichen planus-like reaction. (Hematoxylin-eosin stain;  $\times$  100.) (from Bauer F: *Australas J Dermatol* 19:9-12, 1978.)

Fig. 10. Histopathology of lichen planus in upper part of section, overlying squamous cell carcinoma. (Hematoxylin-eosin stain;  $\times$  100.) (From Bauer F: *Australas J Dermatol* 19:9-12, 1978.)

ously. Active sequelae **occurred** only in those patients who suffered from a severe lichenoid or exfoliative eruption which had led to permanent, inactive sequelae.

I. The active lesions were subdivided into recent lesions in previously grossly damaged skin and chronic lesions present ever since the war.

- a. The recent lesions consisted of two lichen planus nodules forming on grossly damaged skin, histologically lichen planus-like (Figs. 7 and 8) and occurring several years after the war.
- b. Fungating warty growths, first noted 11 years after the war, were situated on the palms (two lesions). The histopathology suggested hypertrophic lichen planus and, in other areas, pseudoepitheliomatous hyperplasia.
- c. Peculiar red plaques (Figs. 3 and 6), sharply margined and at times becoming scaly, starting 14 years after the war, involved mainly the palmar aspect. Three lesions were then described, but since compiling this report, nine more lesions

were observed. Histopathology showed mainly a lichen planus-like picture (Fig. 9) occasionally interspersed with eczematous changes.

2. The chronic lesions which were observed were subdivided into those continuously present since the war and intermittent lesions.

- a. Atrophic purplish and silvery scaly changes on the soles of the feet (Fig. 4) were seen in four patients.
- b. Intermittent ulceration in leukoplakic areas of the tongue were observed in one patient.

Slightly over 120,000 Australians from the State of Victoria served in the Southwest Pacific and took suppressive antimalarials. Walker, the Australian War historian, stated that overall one in 2,000 Australian servicemen suffered from this type of quinacrine dermatitis, even though a higher percentage was at times involved in hyperendemic areas. It is generally recognized that 20% of the patients with quinacrine eruption




Fig. 11. Early malignant changes in peculiar red plaque. Histopathology of lichen planus with central senile keratosis. (Hematoxylin-eosin stain; X50.)

Table I

Criterion	Geometric mean (months) when atrophic sequelae are:		Test	Probability of <sup>no</sup> real difference
	Present	Absent		
Time till dermatitis began	4.14	7.38	$t_{31} = 2.87$	Less than 1%
Total duration of quinacrine ingestion	8.28	12.45	$t_{30} = 2.14$	Less than 5%

suffered from the lichenoid or exfoliative phase,<sup>14</sup> which would be one in 10,000, and therefore  $12 \pm$  an unknown quantity of servicemen in Victoria were expected to be involved in such a way. Nine patients out of approximately twelve were found to have permanent sequelae of some degree. This high percentage of involvement may be due to the fact that the Victorian cases have been followed intensively and for a longer period of time.

While quinacrine was a more toxic drug in higher daily maintenance dose, causing side effects in a relatively greater number of servicemen, in my experience the *severity of permanent sequelae* in the skin did not depend on the daily or total dosage which was taken during the war, but upon *the skin reaction of the patient and his sensitivity to the drug*. Servicemen with the lichenoid and exfoliative skin reactions who had a lichen planus histopathology suffered frequently from

permanent sequelae, while soldiers with an eczematous reaction rarely, if at all, developed permanent damage.

This series of eleven patients and another group of twenty-two American ex-servicemen (whose data were provided by courtesy of Dr. I. L. Schamberg) were examined as to the length of time that they took quinacrine as a <sup>recessive</sup> suppressive antimalarial until the onset of their drug eruption, and as to the length of time it then took to discontinue the offending drug.

Dr. Russell Langley, of the Applied Psychology Department, Caulfield Institute of Technology Melbourne, reevaluated the combined American and Australian figures statistically (Table I). The patients were divided into two groups, one with and the other without atrophic sequelae. This type of division was undertaken because, in my series, only patients with the lichenoid and exfoliative

phases had suffered from permanent atrophic sequelae.

Dr. Langley found that, as usual in cases like this, the durations in Bauer's Table II<sup>14</sup> have quite marked positive skewness and appear to be log-normally distributed. The appropriate central measure for each group's duration is therefore a geometric mean.

There is a significance in the shorter average time interval before the drug eruption became apparent in patients with atrophic sequelae, compared with patients without atrophic sequelae. Also, the total dosage of quinacrine taken by patients with atrophic sequelae was significantly reduced, but to a lesser degree. These findings suggest that the first group of patients were more vulnerable and therefore more likely to suffer from permanent damage to their skin. In addition to this, damage to the patients' skin may have been caused by the fact that these more sensitive patients had to take the offending drug for a relatively longer time after their drug eruption became apparent than did the less sensitive patients.

A type of late sequelae, previously not reported in the literature, occurred in a patient suffering from anhidrotic tropical asthenia of a severe degree. On account of his inability to regulate his body temperature efficiently, he was advised, by his dermatologist, to leave for a cooler climate, namely, Melbourne. Soon after his arrival he was employed as a gasoline pump attendant. Unfortunately, he struck a heat wave a few days after his arrival, with temperatures reaching 39° C. He collapsed while working at the garage, became unconscious and paralyzed, and was admitted to an adjacent hospital and treated for cerebral hemorrhage due to a cerebrovascular accident. Later, as he was an ex-serviceman, he was admitted to the Veterans Hospital, where it became obvious from his medical file and the clinical picture that he suffered from heatstroke.

His rectal temperature was raised to 42° C, and his cerebrospinal fluid contained red blood cells. When he became conscious, he was found to suffer from left-sided hemiplegia, palsy of the right upper extremity, and nystagmus. His neurologic signs, 1 year later, had improved slightly.

In 1978, Bauer<sup>15</sup> described a series of ten squa-

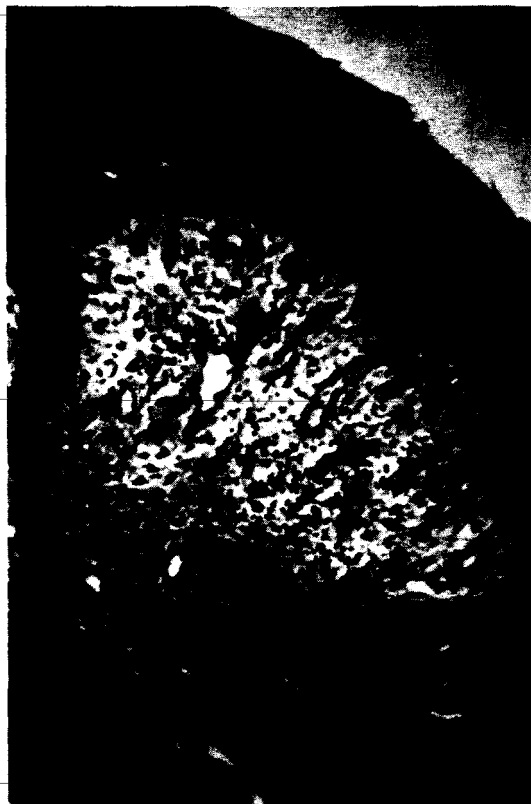

Fig. 12. Early malignant changes in peculiar red plaque. Very early malignant transformation showing cytologic atypia. (Hematoxylin-eosin stain; x200.)

mous cell carcinomas (SCCs), nine of which were situated, primarily or by extension, on the palmar surface, a most unusual location. These SCCs occurred in the three most severely involved ex-servicemen of a larger series reported previously and observed since the war. During the war, these three patients had suffered from severe involvement of their palms and soles, which took over 12 months to clear up and which had led to permanent sequelae. Two of these patients suffered from anhidrotic asthenia of a very marked degree. Eight of these SCCs developed in peculiar red plaques (Figs. 5 and 10), one from a fungating warty growth sequela and one on a grossly atrophic skin of an earlobe. Peculiar red plaques, one of the active sequelae, became malignant in these series as early as 15 years after they were first observed. One of the two areas of fungating warty growths observed transformed into a low-grade malignancy. The second, which was excised, did not



Fig., 13. Early malignant changes in peculiar red plaque. More advanced progress toward malignant change. (Hematoxylin-eosin stain; X50.)

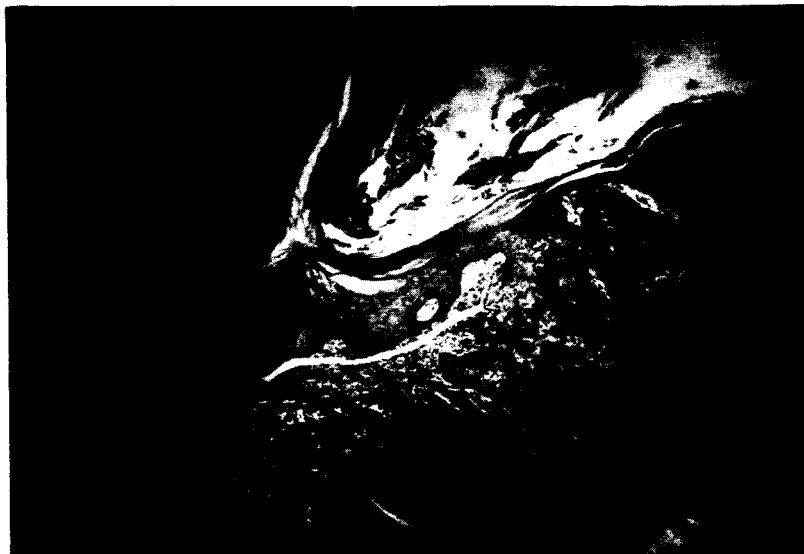


Fig. 14. Lichen planus-like feature on left half of section transforming into a squamous cell carcinoma on the right half of section. (Hematoxylin-eosin stain; X50.) (From Bauer F: *Australas J Dermatol* 19:9-12, 1978.)

reveal such changes. Two of three patients had metastases to their axillae, and one of these areas of metastases was more anaplastic than the primary lesion. Two excised specimens showed multiple malignant lesions (Fig. 5), which indicated their strong malignant potential. Three peculiar red plaques, which were excised early in

their development, did not show any malignant change.

Early malignant changes superadded on a lichen planus histopathology (Figs. 11 to 13) were frequently observed in peculiar red plaques.

A considerable number of the excised specimens of malignant transformation of Peculiar red

has been demonstrated to be there for at least six years after ingestion; it may even be retained permanently in the terminal portion of the sweat ducts. After sweat retention the ducts burst at times and the drug may then be deposited into the tissue. Atabrine is a positively charged drug whilst the terminal part of the sweat ducts is characterised by electro-physiological negativity. The positively charged drug attaches to the negative terminal portion of the sweat duct. This diminishes the propulsion of sweat through the ducts as it interferes with the electrophysiological potential which facilitates sweat transport. Consequently this leads to the slowing up of sweat secretion, retention of sweat, bursting of terminal ducts and to damage and destruction of sweat apparatus.

The fact that the ingestion of quinacrine causes damage to the sweat apparatus" is generally acknowledged. It is surmised that this type of damage causes traces of quinacrine to be deposited in the skin, and this in turn may lead to reactivation of lichen planus-like sequelae many years later. Again, after many more years, some of these late sequelae, particularly peculiar red plaques, will become frankly malignant.

Black<sup>20</sup> reported that lichen planus, whether idiopathic or drug-induced, may be initiated by a cell-mediated immunologic response to an induced antigenic change in skin or mucosa.

Alario et al<sup>21</sup> further confirmed Black's report. Could this cell-mediated immunologic response to antigen (in our patients quinacrine) be one of the triggering mechanisms of the malignant transformation of our patients?

In conclusion, considerable evidence has been submitted to support the view that quinacrine was the most important factor producing these unusually situated malignancies in our patients.

I thank the editor, Dr. R. Becke, and the Editorial Board of the *Australian Journal of Dermatology* for their permission to utilize several photographs which were previously used in two of my papers.

#### REFERENCES

- Rosenthal J: Atypical lichen planus. *Am J Pathol* **22**:473-491, 1946.
- Wilson DJ: Eczematous and pigmentary lichenoid dermatitis: Atypical lichen planus. *Arch Dermatol Syph* **54**:377-391, 1946.
- Bereston ES, Saslow MS: Complications of lichenoid dermatitis: Glomerulonephritis and severe pigmentary changes in exfoliative stage of lichenoid dermatitis. *Arch Dermatol Syph* **54**:325-329, 1946.
- Agress CM: Atabrine as cause of fatal exfoliative dermatitis and hepatitis. *JAMA* **131**:14-21, 1946.
- Walker AS: Australia in the war of 1939-1945. Series V. Medical volume 1. Canberra, A.C.T., 1952. Publisher, Australian War Memorial, p. 639.
- Sulzberger MB, Baer L: Editorial comment. *Year Book of Dermatology and Syphilology*. Chicago. 1946. Year Book Medical Publishers, Inc., pp. 210-211.
- Walker AS: Australia in the war. Medical, the Island Campaign. Canberra, A.C.T., 1957. Publisher, Australian War Memorial, p. 368.
- Nisbet TW: New cutaneous syndrome occurring in New Guinea and adjacent islands. Preliminary report. *Arch Dermatol Syph* **52**:221-225, 1945.
- Bazemore JM, Johnson HH, Swanson ER, Hayman SM: Relation of quinacrine hydrochloride to lichenoid dermatitis. *Arch Dermatol Syph* **54**:308-324, 1946.
- Schmitt CL, Alpino O, Chambers G: Clinical investigations of new cutaneous entity. *Arch Dermatol Syph* **52**:226-238, 1945.
- Schmitt CL: Present status of quinacrine (Atabrine) dermatitis. Report of six cases. *Arch Dermatol Syph* **59**:16-21, 1949.
- Schamberg IL: Studies on Atabrine dermatitis. I. Long term observation on veterans with permanent atrophic residua of the disease. *J Invest Dermatol* **17**:85-98, 1951.
- Schamberg IL: Studies on post Atabrine dermatitis II. Permanent anhidrosis, anhidrotic asthenia and prolonged dermatitis following Atabrine dermatitis. *J Invest Dermatol* **21**:279-292, 1953.
- Bauer F: Sequelae of Atabrine dermatitis in Australian ex-servicemen. *Australas J Dermatol* **6**:311-319, 1962.
- Bauer F: Late sequelae of Atabrine dermatitis—a new pre-malignant entity. *Australas J Dermatol* **19**:9-12, 1978.
- Miller OB, Herrmann F, Rubin J: Effects of meparacrine hydrochloride (Atabrine) on human skin. *J Invest Dermatol* **15**:445-452, 1950.
- Herrmann F, Miller OB: I. Clinical and experimental observations. *Acta Derm Venereol (Stockh)* **32**:304-316, 1952.
- Herrmann F, Miller OB: II. Microscopic studies of vital staining effects in skin. *Acta Derm Venereol (Stockh)* **32**:317-332, 1952.
- Sulzberger MB, Herrmann F, Zak FG: Studies of sweating. I. Preliminary report with particular emphasis on sweat retention syndrome. *J Invest Dermatol* **9**:221-242, 1947.
- Black MM: What is going on in lichen planus? *Clin Exp Dermatol* **2**:303-310, 1977.
- Alario A, Ortonne JP, Schmitt D, Thivolet J: Lichen planus: Study with anti-human T lymphocyte antigen (antiHTLA). *Br J Dermatol* **98**:601-604, 1978.